

TITLE: Reduction of foveal bulges and other anatomical changes in fellow eyes of patients with unilateral idiopathic macular hole without vitreomacular pathologic changes

ABBREVIATED TITLE: Fellow eyes of idiopathic macular hole

AUTHORS: Barbara Delas¹, MD; Gemma Julio^{2,3} PhD, Álvaro Fernández-Vega² MD; Ricardo P Casaroli-Marano⁴ PhD⁴, Jeroni Nadal² MD, PhD.

¹ Department of Ophthalmology, Hospital de Terrassa-Consorci Sanitari de Terrassa (Terrassa, Barcelona, Spain)

² Centro de Oftalmología Barraquer, Barcelona, Spain

³Optics and Optometry Department. Universitat Politècnica de Catalunya-Barcelona Tech

⁴Department of Surgery and Hospital Clinic de Barcelona (IDIBAPS), School of Medicine, Universitat de Barcelona, Barcelona, Spain.

Corresponding author

Barbara Delàs

Hospital de Terrassa, Consorci Sanitari de Terrassa. Ctra Torrebonica s/n.
Terrassa 08227. Barcelona. bdelas@cst.cat.

The results of this study have been partially presented in the 16th EURETINA (European Society of Retina Specialists) Congress in Copenhagen the 9th September 2016.

No authors have a proprietary interest in this work. No funding was received for this work from any organization

KEYWORDS

Idiopathic macular hole, fellow eyes, optical coherence tomography, foveal bulges, inner retinal complex thickness, cone outer segment tips.

SUMMARY STATEMENT

Fellow eyes of idiopathic macular hole without vitreomacular pathologic changes tended to show reduced foveal bulges and inner retinal complex thickness with significantly higher cases with cone outer segment tips alterations than eyes of healthy controls.

ABSTRACT

Purpose: To compare the foveal characteristics in fellow eyes (FE) of patients with unilateral idiopathic macular hole, without vitreomacular pathologic changes, with eyes of healthy controls.

Methods: Forty-seven FE and 52 eyes of 52 age and sex matched healthy controls were studied. Quantitative assessment of the dome-shaped appearance of the hyperreflective lines that represent external limiting membrane (ELM_bulge) and inner outer segment junctions (IS/OS_bulge) were made by optical coherence tomography (OCT) images. Inner retinal complex thickness (IRCT) was quantitatively assessed at 1000 and 2000 μm of the foveal center in nasal and temporal quadrants. Presence of alterations in the inner retinal outer layers and central foveal thickness (CFT) were also analyzed.

Results: Significantly lower ELM_bulge ($p < 0.0001$; Mann-Whitney test) and IS/OS_bulge ($p < 0.001$; student t test) and higher cases with COST alterations, expressed as a diffuse line ($p < 0.006$; Chi2 test) were found in FE than control eyes. IRCT were significantly reduced in FE at all the studied locations when comparing to control eyes ($p < 0.05$; student t test), maintaining anatomical proportionality among locations.

Conclusion: FE without pathologic vitreomacular interactions seems to present some central cone alterations that may be related to other causes than vitreomacular traction.

INTRODUCTION

Earlier histologic studies on the development of the fovea described a centripetal migration of the cone photoreceptors toward the central fovea, thus increasing cone density [1,2]. The central foveal cones undergo both a thinning in width and an increase in length¹ for achieving a higher cone density. This elongation contributes to construct the foveal bulge in normal eyes.

The foveal bulge has been previously described by Optical Coherence Tomography (OCT) images, as the dome-shaped appearance of the hyperreflective line that represents the photoreceptor inner and outer segment junctions (IS/OS) at the foveal center of healthy eyes [3]. As the hyperreflective line that represents the external limiting membrane (ELM) also shows dome-shaped appearance, we have named both structures as IS/OS_bulge and ELM_bulge.

Several studies have assessed the functional relevance of the presence or absence of both foveal bulges (called with different names in the studies). Evidence suggests clear positive correlations with visual acuity in albinism [4,5], occult macular dystrophy [6], amblyopia [7], macular edema associated with branch retinal vein occlusion [3], after vitrectomy for epiretinal membrane [8] or vitreomacular traction syndrome [9], among others clinical situations. Nevertheless, to our knowledge, these structures have not been assessed in fellow eyes (FE) of patients with unilateral idiopathic macular hole (IMH).

IMH is a full-thickness defect of retinal tissue involving the fovea and thus affecting central visual acuity [10]. The prevalence of IMH is approximately 0.05% to 0.3%, more common in females than males, and usually occur after

age 55 [11]. There is a high rate of macular hole formation in the fellow eye (10% to 15%) in the 5-year period after the first macular hole occurs [12-14]. For patients knowing the risk of bilateral IMH is very important. Although the cause of IMH is generally accepted to be vitreomacular traction and tangential traction of the inner limiting membrane [15], the exact pathogenic mechanisms are still elusive. In fact, other factors, as local vascular alteration, has been shown to play a role in the formation of IMH [16,17]. Additional information concerning FE conditions may improve the knowledge about IMH pathogenesis and help predict the risk of bilateral disease.

The aim of this study was to compare the foveal bulges (ELM_bulge and IS/OS_bulge) and other foveal characteristics in FE of patients with unilateral idiopathic macular hole, without vitreomacular pathologic changes, with eyes of healthy controls.

METHODS

Patients

Sixty-two fellow eyes (FE) of 62 patients underwent unilateral full-thickness IMH with a stage 2, 3 or 4 were retrospectively selected in this observational case-control study. The patients were first examined in Centro de Oftalmología Barraquer, Barcelona, Spain and in CST-Hospital de Terrassa, Terrassa, Spain between January 2010 and September 2016. The ages ranged from 41 to 90 years (mean 67 ± 8 years). Exclusion criteria were epiretinal membrane, vitreomacular traction, myopia $> -6.0D$ or axial length >26 mm, amblyopia, glaucoma, history of ocular traumatism or retinal disease other than IMH, any

previous retinal laser or retinal surgery, poor image quality because of unstable fixation or severe cataract, and any associated systematic disorders that might affect eyes. We excluded any retinal disorder that affecting cones, could trigger the disappearance of foveal bulges.

Fifty-two healthy eyes of 52 patients with similar age, sex and axial length than FE group, without retinal or systemic pathologies that might affect the eyes or ocular surgery within 6 months, served as controls. The control patients signed a written informed consent form after the nature of procedures had been explained fully. Procedures were approved by the Ethics Committees of the Centro de Oftalmología Barraquer and the Consorci Sanitari deTerrassa and adhered to the tenets of the Declaration of Helsinki.

Foveal analysis

OCT images of the fovea of FE (at the time of the first IMH diagnosis) and control eyes were obtained using Cirrus HD-OCT 4000 (Carl Zeiss Meditec Inc., Dublin, CA). Conventional cross-sectional B-scans passing through the fovea were analyzed. The images were acquired using the 5-line raster mode, to analyze external and internal retinal layers of the entire foveal area with high-quality images of horizontal and vertical 6 mm scans. The macular cube mode was also used to automatically obtain central foveal thickness (CFT). Eyes with vitreomacular adhesion were identified, according to the International Vitreomacular Traction Study Group Classification [18].

Outer retinal layers, external limiting membrane (ELM), inner outer segment junction (IS/OS), and cone outer segment tips (COST), were classified by three

masked experienced investigators according to the presence/absence of irregularities by OCT images.

Domelike appearance of the inner outer segment junction (IS/OS_bulge) and the external limiting membrane (ELM_bulge) were quantitatively assessed. Specifically, IS/OS_bulge was the distance between the IS/OS line and RPE at the foveal center. Similarly, ELM_bulge was called the distance between the ELM line and RPE at the foveal center. The three masked observers manually measured the foveal bulges using software calipers. Mean value of the three measurements was used for statistical purpose.

Inner retinal complex thickness (IRCT) was also measured from the nerve fiber layer to the inner nuclear layer, in nasal and temporal side, at 1000 (IRCT1) and 2000 μm (IRCT2) from the center of the fovea. All the measurements were made by a masked observer.

Statistical analysis

After an exploratory analysis of the data, continuous variables were tested for normality by the Kolmogorov-Smirnov test. Comparisons between groups were carried-out using Chi2 test and Fisher's exact test for categorical data of outer retinal layers and student t test or Mann-Whitney test for numerical variables (IS/OS_bulge, ELM_bulge, IRCT and CFT). In intra-eye ICRT comparisons paired t test was used. A p value of less than 0.05 was considered statistically significant. Statistical analysis was performed using SPSS V22 (SPSS Inc, Chicago, IL).

RESULTS

From the 62 FE initially selected 9 showed epiretinal membrane and 6 vitreomacular traction and were excluded from the study. Therefore, the 47 FE finally included in this study had a normal macula with a normal foveal contour at the initial examination. The eyes were from 20 males and 27 females (57%) mean age 67 ± 9 years (range 41-90 years). Vitreomacular adhesion (partial detachment of the vitreous in the perifoveal area without retinal abnormalities) was found in 6/47 FE and 10/52 controls with non-significant differences between groups ($p > 0.05$; Chi2 test).

Table 1 presents summary statistics of CFT, ELM_bulge and IS/OS_bulge, and percentage of cases with ELM, IS/OS and COST with alterations in both, FE and control group. Significantly lower ELM_bulge ($p < 0.0001$; Mann-Whitney test) and IS/OS_bulge ($p < 0.001$; student t test) and higher cases with COST alterations, expressed as a diffuse line ($p < 0.006$; Chi2 test) were found in FE than control eyes (Figure 1 and 2). The other studied characteristics were non-significantly different. Optical coherence tomography examination was done by conventional cross-sectional B-scans passing through the fovea, both horizontally and vertically, and comprised five high definition radial scans 6mm long with the 5-line raster mode. For all OCT recordings in our daily practice, care is always taken so that one of the scans passes through the center of the fovea, specially in retinal disorders where automatic fovea location can fail. While exploring, if the fovea location is not clear, multiple explorations are taken in order to ensure we're recording the fovea scan.

In our study, however, the analysis was done on healthy fellow eyes, so that software automatic fovea location was possible. As the instructions given were to take the highest measurement if there was a difference in between two hypothetical foveal scans, if the correct foveal scan was the one we didn't take, that would mean that differences with the control group would have been even more significant.

About IRCT assessment, the summary statistics of the variables at the 4 localizations are showed in table 2. IRCT in FE were significantly reduced in all the studied locations when comparing to control eyes ($p < 0.05$; student t test; see Table 2).

Intra-eye IRCT comparisons revealed that FE tended to maintain normal anatomical proportionality among locations. In this sense, as in control eyes, nasal IRCT were significantly higher than temporal and IRCT1 tended to be higher than IRCT2 in the same quadrant ($p < 0.003$ in all the comparisons for both groups; paired t test).

The recorded follow up revealed that 4 (9%) FE developed IMH between 4 and 14 months after the first diagnosis (mean time 11 months). Three of them showed VMA at the first visit.

DISCUSSION

The findings showed that FE displayed similar CFT, ELM, and IS/OS than control eyes but with a significant higher tendency for COST alterations, reduced ELM_bulge, IS/OS_bulge and IRCT, maintaining anatomical IRCT

differences between studied localizations (at 1000 and 2000 μm of the foveal center) and quadrants. Reduction in foveal ELM and IS/OS bulges have been previously described for other retinal disorders, but have never been described for healthy eyes before, as FE are considered.

The main contribution of this study is the evidence that central foveal cones of FE, with normal macula and foveal contour, tended to be shorter than in control eyes. These anatomical changes are in agreement with functional alterations showed in FE, such as damaged chromatic and achromatic processing found by spectral sensitivity [19]. In addition, Brich and coworkers [20] found tendency for reducing foveal cone focal electroretinogram in FE. The authors concluded that the dysfunction could result from decreased optical density because of shortened or misaligned cone outer segments. This anatomical alteration could be expressed as a reduction in ELM and IS/OS bulges by OCT, as findings of the present study showed for the first time.

Until now, all the anatomical photoreceptor changes previously described in FE were found in eyes that underwent some degree of pathological vitreomacular detachment. Hypothetically the tractional force would reach the outer retina via the radiating Müller cell processes [8, 21, 22] and subsequently damage the photoreceptors, disturbing the COST line leading to a triangular central COST detachment [23, 24] or enlarging foveal bulges in eyes with symptomatic vitreomacular traction (Ichiyama et al). In the present study no vitreomacular traction cases were included and number of vitreomacular adhesion (described as a stage zero macular holes by Chan and coworkers [25]), were similar in both FE and control eyes. Therefore, tractional forces seem not to be the main cause of the shortening of ELM and IS/OS bulges found in our results.

A plausible cause of the reduced ELM and IS/OS bulges in FE without vitreomacular traction may be the thinner subfoveal choroidal thickness describe previously when comparing FE with age and sex matched control eyes, using enhanced depth imaging OCT [26, 27]. In addition, the negative correlation between subfoveal choroidal thickness and age, showed in both groups, was weaker in IMH eyes and fellow eyes than in control eyes, which suggests that the thinning of the choroid in IMH and fellow eyes is, at least, partially due to some reasons other than aging. Indeed, the choroid contributes blood supply to the outer retina and in the foveal avascular zone this contribution represents the 100% blood and oxygen supply because of the lack of retinal vessels. Trophic and vascular alterations have been hypothesized in eyes with IMH and FE [17, 27-29]. Despite evidence provided, the relationship between choroidal hypoperfusion and reduction of foveal bulges requires further studies to definitively be confirmed.

Another remarkable finding of the present study was the significantly higher percentage of COST alterations in FE, expressed as a diffuse line. It is well known that photoreceptors account for much of the oxygen consumed by the retina. Mathematical analysis revealed a remarkable heterogeneity of oxygen requirements of different components of the outer retina, with the inner segments of the photoreceptors being the dominant oxygen consumers [30, 31]. When metabolic changes affect photoreceptor anatomy, COST seems to be the first layer to be disorganized. For instance, it is well described that in retinitis pigmentosa metabolic changes cause decrease transport of newly synthesized proteins from the photoreceptor inner to the outer segment, shorting outer

segments [32-34] and COST disorganization is the first sign of photoreceptor alteration. The COST layer seems to be a readily affected structure that only in favorable conditions becomes restored. It is well known that after IMH surgery, outer retinal layers become renovated first at the ELM, followed by the IS/OS and finally the COST [35-37]. Additionally, the relatively high number of cases of control eyes with COST alterations found in the present study may be also due to a reduction of subfoveal choroidal thickness, in this case exclusively produced by patient age, as commented before [26].

FE also displayed a significant tendency for IRCT reduction in all the locations and quadrants, maintaining anatomical proportions. This change may be mainly related to photoreceptors alterations in the absence of pathogenic vitreous traction. Remodeling of the neural retina has been described in the first stages of several pathologies with photoreceptor degeneration and consists in gradual morpho-functional changes, which mainly involve neurons and glia, leading to alterations in the topology and stratification of the retina and the consequent change of synaptic relations in an effort to maintain tissue functionality [38, 39]. The fact that anatomical proportions in IRCT were respected in FE could indicate that this process of remodeling might be in a first stage. Further assessments will be necessary to elucidate this question.

Finally, bilateral IMH was recorded in 9% of the FE but, given the retrospective nature of the study and the lack of exhaustive follow up, this percentage may be higher. New prospective studies will be required to analyze the relationship between the anatomical photoreceptor alterations described in this study and the presence of bilateral IMH and functional changes in FE with normal vitreomacular interface.

In summary, FE without pathologic vitreomacular interactions seems to present some central cone alterations expressed as reduced ELM and IS/OS bulge, with increased of mild COST changes, and tendency for thinner IRCT, maintaining anatomical proportions in the studied locations. Choroidal hypoperfusion may be the cause of these modifications with pathologic and functional consequences yet to be determined.

REFERENCES

- [1] Yuodelis C, Hendrickson A. A qualitative and quantitative analysis of the human fovea during development. *Vision Res* 1986;26(6):847–855.
- [2] Hendrickson A, Possin D, Vajzovic L, Toth CA. Histologic development of the human fovea from midgestation to maturity. *Am J Ophthalmol* 2012;154(5):767–778.
- [3] Hasegawa T, Ueda T, Okamoto M, Ogata N. Presence of foveal bulge in optical coherence tomographic images in eyes with macular edema associated with branch retinal vein occlusion. *Am J Ophthalmol* 2014;157(2):390-396.e1.
- [4] Thomas MG, Kumar A, Mohammad S, et al. Structural grading of foveal hypoplasia using spectral-domain optical coherence tomography a predictor of visual acuity? *Ophthalmology* 2011;118(8):1653-60.
- [5] Mohammad S, Gottlob I, Kumar A, et al. The functional significance of foveal abnormalities in albinism measured using spectral-domain optical coherence tomography. *Ophthalmology* 2011;118(8):1645-52.

- [6] Scholl HP, Birch DG, Iwata T, et al. Characterizing the phenotype and genotype of a family with occult macular dystrophy. *Arch Ophthalmol* 2012;130(12):1554–1559.
- [7] Al-Haddad CE, El Mollayess GM, Mahfoud ZR, et al. Macular ultrastructural features in amblyopia using high-definition optical coherence tomography. *Br J Ophthalmol* 2013;97(3):318–322.
- [8] Hashimoto Y, Saito W, Saito M, et al. Retinal outer layer thickness increases after vitrectomy for epiretinal membrane, and visual improvement positively correlates with photoreceptor outer segment length. *Graefes Arch Clin Exp Ophthalmol* 2014;252(2):219-26.
- [9] Ichiyama Y, Kawamura H, Fujikawa M, et al. Photoreceptor outer segment length and outer foveal thickness as factors associated with visual outcome after vitrectomy for vitreomacular traction syndrome. *Retina* 2016;36(9):1707-12.
- [10] Ho AC, Guyer DR, Fine SL. Macular hole. *Surv Ophthalmol* 1998;42:393–416.
- [11] American Academy of Ophthalmology Retina/Vitreous Panel. Preferred Practice Pattern® Guidelines. Idiopathic Macular Hole. San Francisco, CA: American Academy of Ophthalmology; 2014. Available at: www.aao.org/ppp.
- [12] Ezra E, Wells JA, Gray RH, et al. Incidence of idiopathic full-thickness macular holes in fellow eyes. A 5-year prospective natural history study. *Ophthalmology* 1998;105:353-9.

- [13] Freeman WR, Azen SP, Kim JW, et al. Vitrectomy for the treatment of full-thickness stage 3 or 4 macular holes. Results of a multicentered randomized clinical trial. The Vitrectomy for Treatment of Macular Hole Study Group. Arch Ophthalmol 1997;115(1):11-21.
- [14] Kim JW, Freeman WR, Azen SP, et al, Vitrectomy for Macular Hole Study Group. Prospective randomized trial of vitrectomy or observation for stage 2 macular holes. Am J Ophthalmol 1996;121:605-14.
- [15] Gass J. Reappraisal of biomicroscopic classification of stages of development of a macular hole. Am J Ophthalmol 1995; 119:752–9.
- [16] Aras C, Ocakoglu O, Akova N. Foveolar choroidal blood flow in idiopathic macular hole. Int Ophthalmol 2004;25:225–31.
- [17] Gass JD. Idiopathic senile macular hole: its early stages and pathogenesis. Arch Ophthalmol 1988;106:629 –39.
- [18] Duker JS, Kaiser PK, Binder S, et al. The International Vitreomacular Traction Study Group classification of vitreomacular adhesion, traction, and macular hole. Ophthalmology 2013;120(12):2611-9.
- [19] Sharanjeet-Kaur, O'Donoghue E, Murray IJ. Spectral sensitivity in eyes with macular holes and their fellow eyes. Clin Exp Optom 2003;86(6):385–389.
- [20] Birch DG, Jost BF, Fish GE. The focal electroretinogram in fellow eyes of patients with idiopathic macular holes. Arch Ophthalmol 1988;106(11):1558-63.

- [21] Gass JD. Müller cell cone, an overlooked part of the anatomy of the fovea centralis: hypotheses concerning its role in the pathogenesis of macular hole and foveomacular retinoschisis. *Arch Ophthalmol* 1999;117(6):821-3.
- [22] Yamada E. Some structural features of the fovea centralis in the human retina. *Arch Ophthalmol* 1969;82:151–159
- [23] Takahashi A, Nagaoka T, Yoshida A. Stage 1-A macular hole: a prospective spectral-domain optical coherence tomography study. *Retina* 2011;31(1):127-47.
- [24] Uemura A, Otsuji F, Nakano T, Sakamoto T. Vitreomacular interface and outer foveal microstructure in fellow eyes of patients with unilateral macular holes. *Retina* 2014;34(6):1229-34.
- [25] Chan A, Duker JS, Schuman JS, Fujimoto JG. Stage 0 macular holes: observations by optical coherence tomography. *Ophthalmology* 2004;111(11):2027-32.
- [26] Zeng J, Li J, Liu R, et al. Choroidal thickness in both eyes of patients with unilateral idiopathic macular hole. *Ophthalmology* 2012;119(11):2328-33.
- [27] Reibaldi M, Boscia F, Avitabile T, et al. Enhanced depth imaging optical coherence tomography of the choroid in idiopathic macular hole: A cross-sectional prospective study. *Am J Ophthalmol* 2011;151(1):112-117.e2.
- [28] Morgan CM, Schatz H. Idiopathic macular holes. *Am J Ophthalmol* 1985; 99(4):437-44.

- [29] Morgan CM, Schatz H. Involutional macular thinning. A pre-macular hole condition. *Ophthalmology* 1986;93(2):153-61.
- [30] Haugh LM, Linsenmeier RA, Goldstick TK. Mathematical models of the spatial distribution of retinal oxygen tension and consumption, including changes upon illumination. *Ann Biomed Eng* 1990;18(1):19-36.
- [31] Yu DY, Cringle SJ. Oxygen distribution and consumption within the retina in vascularised and avascular retinas and in animal models of retinal disease. *Prog Retin Eye Res* 2001;20(2):175-208.
- [32] Barrong SD, Chaitin MH, Fliesler SJ, et al. Ultrastructure of connecting cilia in different forms of retinitis pigmentosa. *Arch Ophthalmol* 1992;110(5):706-10.
- [33] Berson EL, Adamian M. Ultrastructural findings in an autopsy eye from a patient with Usher's syndrome type II. *Am J Ophthalmol* 1992;114(6):748-57.
- [34] Milam AH, Li ZY, Cideciyan AV, Jacobson SG. Clinicopathologic effects of the Q64ter rhodopsin mutation in retinitis pigmentosa. *Invest Ophthalmol Vis Sci* 1996;37(5):753-65.
- [35] Ooka E, Mitamura Y, Baba T, et al. Foveal microstructure on spectral-domain optical coherence tomographic images and visual function after macular hole surgery. *Am J Ophthalmol*. 2011;152(2):283-290.e1.
- [36] Itoh Y, Inoue M, Rii T, Hiraoka T, Hirakata A. Correlation between length of foveal cone outer segment tips line defect and visual acuity after macular hole closure. *Ophthalmology*. 2012;119(7):1438-46.

[37] Itoh Y1, Inoue M, Rii T, Hiraoka T, Hirakata A. Significant correlation between visual acuity and recovery of foveal cone microstructures after macular hole surgery. *Am J Ophthalmol.* 2012;153(1):111-9.e1.

[38] Jones BW, Pfeiffer RL, Ferrell WD, et al. Retinal remodeling in human retinitis pigmentosa. *Exp Eye Res* 2016; 150:149-165.

[39] Marc RE, Jones BW, Watt CB, Stretoi E. Neural remodeling in retinal degeneration. *Prog Retin Eye Res* 2003; 22: 607-55.

FIGURE LEGEND

Figure 1. Typical OCT images on healthy control (top) and fellow eyes (FE) of patients with idiopathic macular hole (bottom). Note the lack of ELM and IS/OS dome shaped appearance (foveal bulges), and the poor discrimination of COST line.

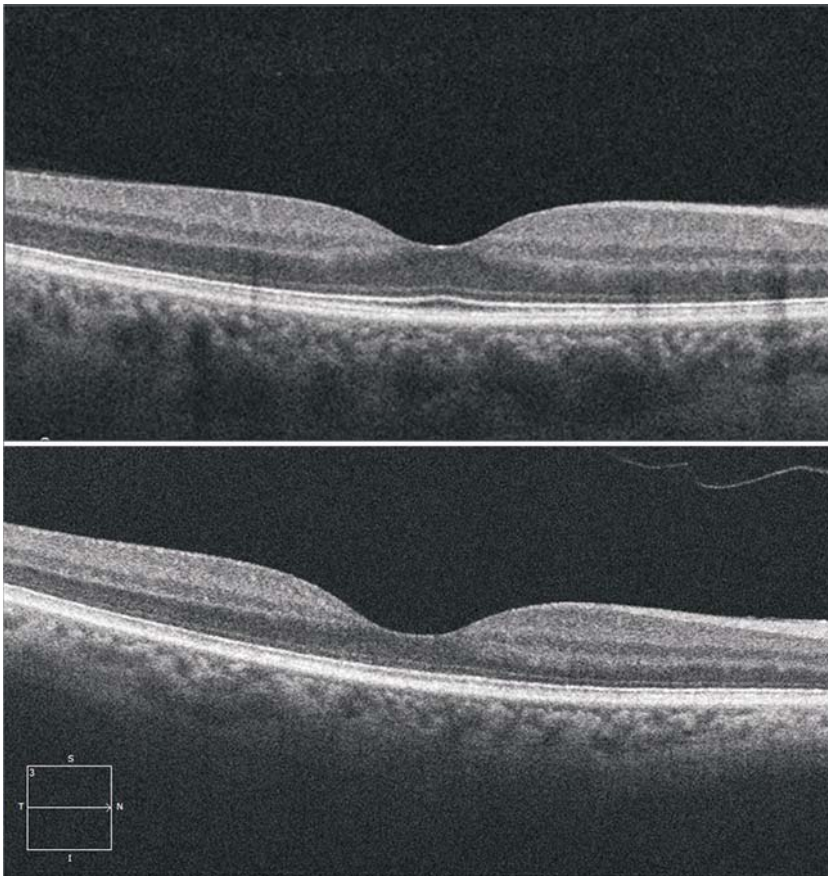


Figure 2. COST line irregularities in fellow eye OCT (right). Note COST differences in the continuous line in healthy control eye.

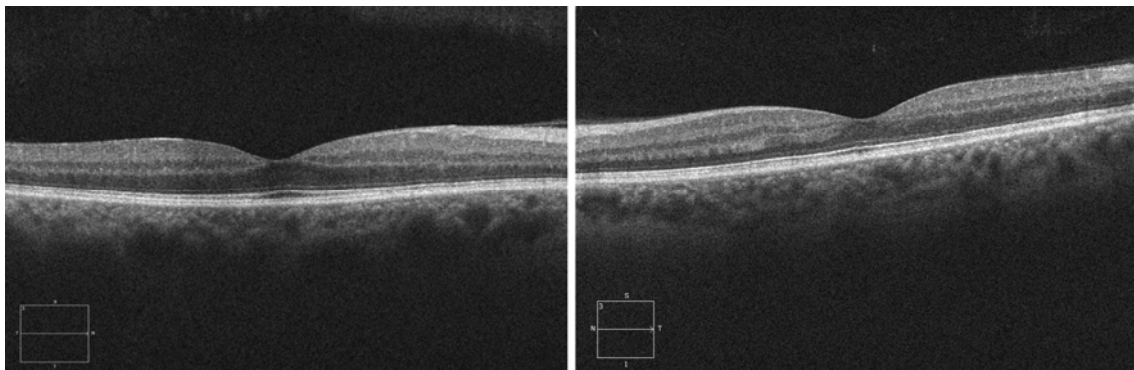


Table 1. OCT outcomes in both, control and FE groups

Variables	Control	FE	p values
CFT (μm)			0.106
Mean (CI 95%)	259 (253-266)	251 (243-259)	
Median	262	246	
SD	23	24	
Min	205	196	
Max	297	310	
ELM_bulge (μm)			0.0001*
Mean (CI 95%)	77 (72-83)	66 (64-69)	
Median	73	68	
SD	19	10	
Min	48	35	
Max	150	89	
EZ_bulge (μm)			0.001*
Mean (CI 95%)	44 (41-45)	38 (35-40)	
Median	42	39	
SD	8	8	
Min	23	16	
Max	65	58	
ELM			1.000
(% of cases with alterations)	2%	2%	
EZ			0.475
(% of cases with alterations)	0%	2%	
COST			0.006*
(% of cases with alterations)	38%	66%	

CI 95% : confidence interval 95%; SD: standard deviation; Min: minimum; Max: maximum;
 *Significant differences. For numerical variable student t test or Mann-Whitney test was applied. For comparisons of categorical variables Fisher exact test or Chi2 test was applied.

Table 2. IRCT summary statistics in control and FE

Variables	Control	FE	p values
IRCT1 N (µm)			0.013*
Mean (CI 95%)	208 (201-215)	195 (187-203)	Mean difference
Median	208	193	13 (CI 95% 3-23)
SD	24	27	
Min	164	141	
Max	257	289	
IRCT2 N (µm)			0.006*
Mean (CI 95%)	196 (190-202)	183 (174-190)	Mean difference
Median	199	179	13 (CI 95% 4-23)
SD	23	24	
Min	138	123	
Max	252	249	
IRCT1 T(µm)			0.0001*
Mean (CI 95%)	178 (174-182)	167 (162-171)	Mean difference
Median	177	169	11 (CI 95% 5-19)
SD	14	15	
Min	136	125	
Max	208	203	
IRCT2 T(µm)			0.041*
Mean (CI 95%)	157 (153-160)	150 (145-156)	Mean difference
Median	156	149	7 (CI 95% 0.3-13)
SD	13	18	
Min	120	114	
Max	192	191	

N: nasal; T: temporal. CI 95%: confidence interval 95%; SD: standard deviation; Min: minimum; Max: maximum; *Significant differences. Student t test was used for comparisons between groups.